

Long-term administration of the fungus toxin, sterigmatocystin, induces intestinal metaplasia and increases the proliferative activity of PCNA, p53, and MDM2 in the gastric mucosa of aged Mongolian gerbils

Masahiro Kusunoki · Junichi Misumi · Tatsuo Shimada · Kazuo Aoki · Noritaka Matsuo · Hideaki Sumiyoshi · Takeshi Yamaguchi · Hidekatsu Yoshioka

Received: 4 August 2010 / Accepted: 27 October 2010 / Published online: 13 January 2011
© The Japanese Society for Hygiene 2010

Abstract

Objective The causal agents of gastric cancer could include fungus toxins. Sterigmatocystin (ST), a fungus toxin, is a risk factor of gastric cancer. We investigated the effects of ST on the stomach tissues of Mongolian gerbils.

Methods Seventy-five-week-old male Mongolian gerbils received ST ad libitum at a concentration of 0 ppb (non-treated, $n = 11$), 100 ppb ($n = 7$), or 1,000 ppb ($n = 13$) dissolved in drinking water for a period of 24 weeks. After administration, we tested the histopathological changes and immunostaining for proliferating cell nuclear antigen (PCNA), p53, and MDM2 expression.

Results We investigated the histopathological changes and determined the incidence of histopathological changes in animals with various gastric diseases after ST administration at a dose of 0 ppb (non-treated control), 100, or 1,000 ppb as follows: firstly, indices for gastritis were 18.2, 100, and 100%, those for erosion events were 9.1, 100, and

92.3%, and those for polyps were 0, 71.4, and 61.5%, respectively. These incidences in the ST-administered groups (100 or 1,000 ppb) showed significant increases compared with those in the non-treated control group. And, lastly, indices for intestinal metaplasia were 0, 100, and 15.4%, respectively. Furthermore, immunostaining for PCNA, p53, and MDM2 expression showed significantly greater rates in the ST-administered groups (100 or 1,000 ppb) than in the non-treated control group.

Conclusion The histopathological and immunohistopathological findings of this study indicate that ST exerts a marked influence on gastric mucus and gland cells, showing dominant gastritis, erosion events, polyps, and intestinal metaplasia in these animals.

Keywords Sterigmatocystin · Intestinal metaplasia · Proliferating cell nuclear antigen (PCNA) · p53 · MDM2

M. Kusunoki (✉) · N. Matsuo · H. Sumiyoshi · H. Yoshioka
Department of Matrix Medicine, Faculty of Medicine,
Oita University, Idaigaoka 1-1, Hasama-machi,
Yufu, Oita 879-5593, Japan
e-mail: e21501@oita-u.ac.jp

J. Misumi · T. Shimada
Professor Emeritus, Oita University, Hasama-machi,
Yufu, Oita 879-5593, Japan

K. Aoki
Department of Public Health and Hygiene,
University of the Ryukyus Faculty of Medicine,
207 Uehara, Nishihara-cho, Okinawa 903-0215, Japan

T. Yamaguchi
Department of Functional Anatomy,
Faculty of Medicine, Kanazawa University,
13-1 Takaramachi, Kanazawa 920-1192, Japan

Introduction

Previous studies in humans have clarified that *Helicobacter pylori* infection induces the infiltration of inflammatory cells into the gastric mucosa [1], which leads to the development of chronic atrophic gastritis, gastric ulcers, duodenal ulcers [2], and gastric cancer [3]. The prevalence of *H. pylori* infection before 1949 was over 70% in Japan [4], and *H. pylori* infection is the major cause of histological gastritis and carcinogenesis in humans [1–3]. However, the death rate from gastric cancer in these patients is unexpectedly low compared with that from other cancers, such as lung cancer in Japan [5]. Furthermore, the prevalence rate of gastric cancer has decreased each year [6]. In addition, half of the patients with early gastric cancer are negative for *H. pylori* antibody [7].

We have speculated that, besides *H. pylori*, there must be other causal agents that produce gastric cancer. The causal agents of gastric cancer could include fungus toxins, which are universally distributed in Asian countries. The genus *Aspergillus*, which is indigenous to human habitats, is known to grow in corn, barley, wheat, peanuts, and walnuts and to produce various mycotoxins [8]. Specifically, the mycotoxin sterigmatocystin (ST), a substance produced by *A. versicolor*, the chemical structure of which has been elucidated, is a precursor of aflatoxin B1. It is also widely distributed in soil, agricultural crops, and grain crops [9]. Xie et al. [10] have shown that *Aspergillus*-inoculated corn flour causes typical hyperplasia of the glandular stomach in mice. In addition, an analysis of diet and gastric juice samples from patients with chronic gastritis in rural regions with high gastric cancer mortality showed that they were frequently contaminated with *A. versicolor* [10].

Truong Minh et al. [11] reported that gastric cancer mortality rates for men and women increase with age. And the deterioration in immune function with aging is thought to make a major contribution to the increased morbidity and mortality from infectious disease with advancing age [12]. Furthermore, elderly people frequently have symptoms of fullness and appetite loss due to impaired gastric motor activity [13].

In our previous study, the administration of ST to *H. pylori*-infected Mongolian gerbils induced a significantly higher incidence of gastric carcinogenesis compared with that in *H. pylori*-infected animals without ST treatment [14]. The above-mentioned study suggests that ST is a potential factor of carcinogenesis on the stomach in Mongolian gerbils. However, to our knowledge, there have been no reports showing that ST alone induces stomach cancer in the experimental animals with aging.

In the present study, we examined whether the fungus toxin, sterigmatocystin, which is produced by fungi such as *A. versicolor* and *flavus*, has a carcinogenetic effect on the gastric mucosa in aged Mongolian gerbils.

Materials and methods

Animals

Seventy-five-week-old male specific pathogen-free Mongolian gerbils (NOs/Sea, Kyudo, Kumamoto, Japan), weighing a mean of 91.6 ± 12.36 g at the beginning of the ST administration, were used in this study. The animals were housed 4–5/cage in an animal room maintained at $23 \pm 2^\circ\text{C}$ with $55 \pm 5\%$ humidity under a 12/12-h light–dark cycle, with free access to food (CE-2; CLEA Japan, Inc., Tokyo) and drinking water. This study was based on

the Guidelines for Animal Experimentation of the Faculty of Medicine, Oita University, Japan, and was approved by its Ethics Committee.

Experimental protocol

Seventy-five-week-old Mongolian gerbils were randomly assigned to the following groups: (1) non-treated control ($n = 11$), (2) ST 100 ppb administration ($n = 7$), and (3) ST 1,000 ppb administration ($n = 13$). ST (3a,12c-dihydro-8-hydroxy-6-methoxy-7H-furo[3',2':4,5]furo[2,3-c]xanthen-7-one) [10048-13-2] was purchased from Sigma Chemical Company (St. Louis, MO, USA), and ST with over 98% purity was used. The LD₅₀ value of ST has been reported to be 166 mg per kg in rats with oral administration [15]. ST was administered for 24 weeks at the specified concentrations in drinking water. In order for this agent to dissolve well in water, ST was dissolved with distilled water over 24 h and then adjusted to the specified concentration. The ST water was made fresh every week, stored at 10°C, and stirred again before administration.

Histological examination

The stomachs were opened along the greater curvature and gastric tissues, including the cardia, body, and antrum, were fixed in 10% neutral formalin solution for more than 4 h dehydrated and then embedded in paraffin. Thereafter, 7- μm -thick sections were stained with hematoxylin and eosin (H&E) for morphological examination or with periodic acid Schiff's (PAS) reaction and Alcian blue (pH 2.5) to detect mucin-containing cells and observed.

All tissue preparations were observed by light microscopy (Nikon, Tokyo) at 50 \times , 100 \times , and 400 \times magnifications. Histopathologic findings of the glandular stomach were categorized as follows: (1) active gastritis, (2) erosion events, (3) hyperplastic polyps, and (4) intestinal metaplasia. These were classified as positive or negative as reported by Watanabe et al. [16] and Ma et al. [17].

Immunohistochemistry

Gastric sections were examined by immunohistochemical staining with mouse anti-proliferating cell nuclear antigen (PCNA) antibody (Nichirei, Inc., Japan), mouse anti-p53 antibody (Nichirei, Inc., Japan), and rabbit anti-MDM2 antibody (Ana Spec, Inc., USA), respectively. The paraffin sections were autoclaved in TE buffer (pH 9.0) for 15 min to retrieve the p53 antigenicity and for 20 min to retrieve the MDM2 antigenicity, or were microwaved in 10 mM citrate buffer (pH 6.0) for 15 min to retrieve PCNA antigen. The slide was subsequently incubated with the primary anti-PCNA for 1 h at room temperature, the primary

anti-p53 for overnight at 4°C, and the primary anti-MDM2 for 40 min at room temperature, together with their respective secondary antibodies (biotin-conjugated anti-immunoglobulin) at room temperature for 10 min, followed by reaction with the streptavidin peroxidase method at room temperature for 5 min.

The PCNA labeling index (LI), p53 positive index (PI), and MDM2 LI expression were evaluated by light microscopy [18, 19]. Three microscopic fields of the gastric body and pyloric region were photographed, and each index was calculated by counting about 1,000 positive and normal nuclei in the selected fields.

Statistical analysis

The gastric sections that were positive for histopathological changes were analyzed by the Chi-square test. Findings of p53 PI and MDM2 were also compared between groups using the Mann–Whitney *U*-test adjusted by the Bonferroni method. Body weight at autopsy and PCNA LI were compared by one-way analysis of variance (ANOVA) followed by Tukey's multiple comparison test.

Results

General findings

Ninety-nine-week-old Mongolian gerbils showed mean body weights in the respective groups as follows: ST non-treated control group 106.1 g, ST 100 ppb-administered group 111.5 g, and ST 1,000 ppb-administered group 86.7 g (Table 1). The mean index of body weight was significantly lower in the ST 1,000 ppb-administered group than in the ST 100 ppb-administered group. Furthermore, the feed consumption ranges during the experimental

period were as follows: ST non-treated-control group 5.5–8.1, ST 100 ppb-administered group 4.5–7.0, and ST 1,000 ppb-administered group 3.9–5.3 (g per animal per day), respectively. And the ST consumption ranges during the administration period were ST 100 ppb-administered-group 0.007–0.015 and ST 1,000 ppb-administered-group 0.088–0.132 (mg per kg per day), respectively. There were no intergroup differences in either feed consumption or water intake.

Histopathological findings

Figure 1 shows the histologically normal appearance of the gastric mucosa and glands from the ST non-treated control group. There were no foci of inflammation in the gastric mucosa.

Macroscopically, in the gastric mucosa of some ST-administered Mongolian gerbils, polyps and edema were found (Fig. 2).

Table 1 shows the incidences of the histopathological changes in the Mongolian gerbils with various gastric diseases after ST administration at a dose of 0 ppb (non-treated control), 100, or 1,000 ppb. Firstly, gastritis was found in 18.2% of the non-treated control, 100% of 100 ppb, and 100% of 1,000 ppb groups. Secondly, erosion events were found in 9.1% of the non-treated control, 100% of 100 ppb, and 92.3% of 1,000 ppb groups. Thirdly, hyperplastic polyps were found in 0% of the non-treated control, 71.4% of 100 ppb, and 61.5% of 1,000 ppb groups. These incidences were significantly greater in both ST-administered groups than those in the non-treated control group. Lastly, intestinal metaplasia was found in 0% of the non-treated control, 100% of 100 ppb, and 15.4% of 1,000 ppb groups. The incidence of intestinal metaplasia was also significantly greater in the ST 100 ppb-administered group than that in either the ST 1,000 ppb-administered group or non-treated control group.

Table 1 Body weight and histopathological changes in the glandular stomach of Mongolian gerbils in the sterigmatocystin (ST)-administered groups

Group	<i>n</i>	Body weight at 99 weeks (g) ^a	Active gastritis ^b	Erosion events ^b	Hyperplastic polyps ^b	Intestinal metaplasia ^b
Non-treated control	11	106.1 ± 19.5	2/11 (18.2)	1/11 (9.1)	0/11 (0.0)	0/11 (0.0)
ST (100 ppb) administration	7	111.5 ^c ± 13.0	7/7 (100.0) ^d	7/7 (100.0) ^d	5/7 (71.4) ^d	7/7 (100.0) ^e
ST (1,000 ppb) administration	13	86.7 ± 22.0	13/13 (100.0) ^d	12/13 (92.3) ^d	8/13 (61.5) ^d	2/13 (15.4)

^a The results represent the mean ± SD. The data were analyzed by one-way analysis of variance (ANOVA) followed by Tukey's multiple comparison test

^b The results show the number of animals that were histopathologically positive/the number of animals examined (the percentage of positive cases). The data were analyzed by the Chi-square test

^c *P* < 0.05 compared with the ST (1,000 ppb) administration group

^d *P* < 0.01 compared with the non-treated control group

^e *P* < 0.01 compared with the non-treated control and ST (1,000 ppb) administration groups

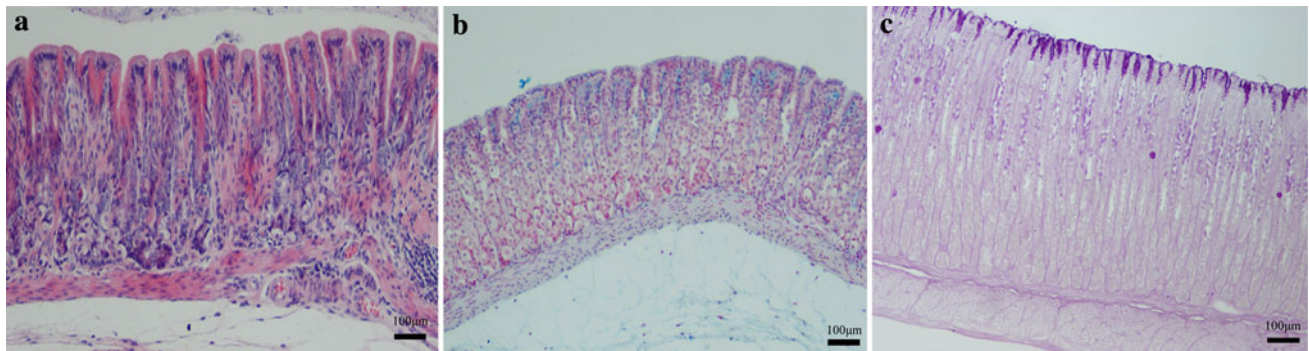


Fig. 1 Light microscopic views of the normal gastric mucosa of Mongolian gerbils. **a** Normal stomach tissue is smooth and without foci of inflammation in the gastric mucosa. **b** Findings in the luminal surface of the normal stomach body. The epithelium is well preserved and Alcian blue staining does not demonstrate acidic

mucin. **c** Periodic acid Schiff's (PAS) reaction is negligible. Characteristics of adenocarcinoma and mucus production are not confirmed. Stains: hematoxylin and eosin (H&E) staining (**a**), pH 2.5 Alcian blue staining (**b**), PAS staining (**c**). Group: non-treated control group (**a–c**)

Figure 3 demonstrates the histopathological findings in the ST-administered Mongolian gerbils. Figure 3a, b shows intestinal metaplasia forming villus-like structures in the mucosal and muscular layers of the pyloric antrum in the ST-administered groups. Mucous cells, which were positively stained with Alcian blue staining, contained acid mucins. Figure 3c shows intensive erosions in the deep regions of the antrum mucosa and Fig. 3d shows polyps with many glands in the mucosa.

PCNA LI, p53 PI, and MDM2 LI expression

Analysis of the effects of dose-dependent ST on the expression of PCNA showed that positive cells were more abundant in the gastric mucosa of the ST 1,000 and 100 ppb administration groups than those in the non-treated control group (Fig. 4a), and extended into the middle of the basal layers of the mucosa. Figure 4b, c show PCNA immunostaining of gastric mucosa from ST 1,000 and 100 ppb-administered Mongolian gerbils, respectively.

The PCNA LI, p53 PI, and MDM2 LI are shown in Table 2. The PCNA LI, p53 PI, and MDM2 LI values in the ST 1,000 and 100 ppb administration groups were significantly greater than those in the non-treated control group.

However, no p53 or MDM2 was detected in the normal part of the gastric mucosa (Fig. 5a, b). The p53- and MDM2-positive cells were observed due to the presence of faintly stained nuclei (Fig. 5c, d), indicating significantly greater expression rates of tumor suppressor genes.

Discussion

The present study demonstrated that long-term administration of the mycotoxin ST induced a metaplastic effect, including increases in the PCNA LI, p53 PI, and MDM2 LI

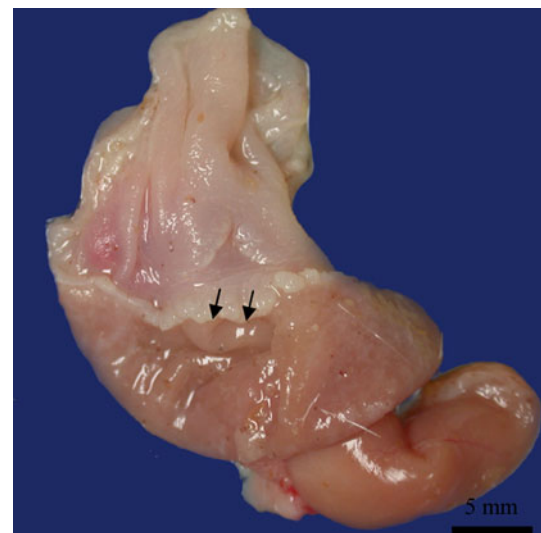


Fig. 2 Macroscopic image of the luminal surface of stomach from sterigmatocystin (ST)-administered Mongolian gerbils. Edema (arrows) in the gastric mucosa is found and the gastric mucosal surface is irregular in appearance. Group: ST 1,000 ppb administration group

expression rates, in the gastric mucosa of Mongolian gerbils. We also found gastritis, erosion events, polyps, and intestinal metaplasia of the gastric mucosa in ST-administered Mongolian gerbils. Histopathological changes for active gastritis and erosion events were found in all animals of both ST administration groups. Active gastritis was marked in the ST 1,000 ppb administration group compared with that in the ST 100 ppb administration group. And ulceration was demonstrated in some gerbils receiving ST 1,000 ppb. Intestinal metaplasia was confirmed in all animals of the ST 100 ppb administration group, but only in 15.4% of the ST 1,000 ppb administration group. The difference in the incidence of intestinal metaplasia might provide a clue to the mechanism underlying the

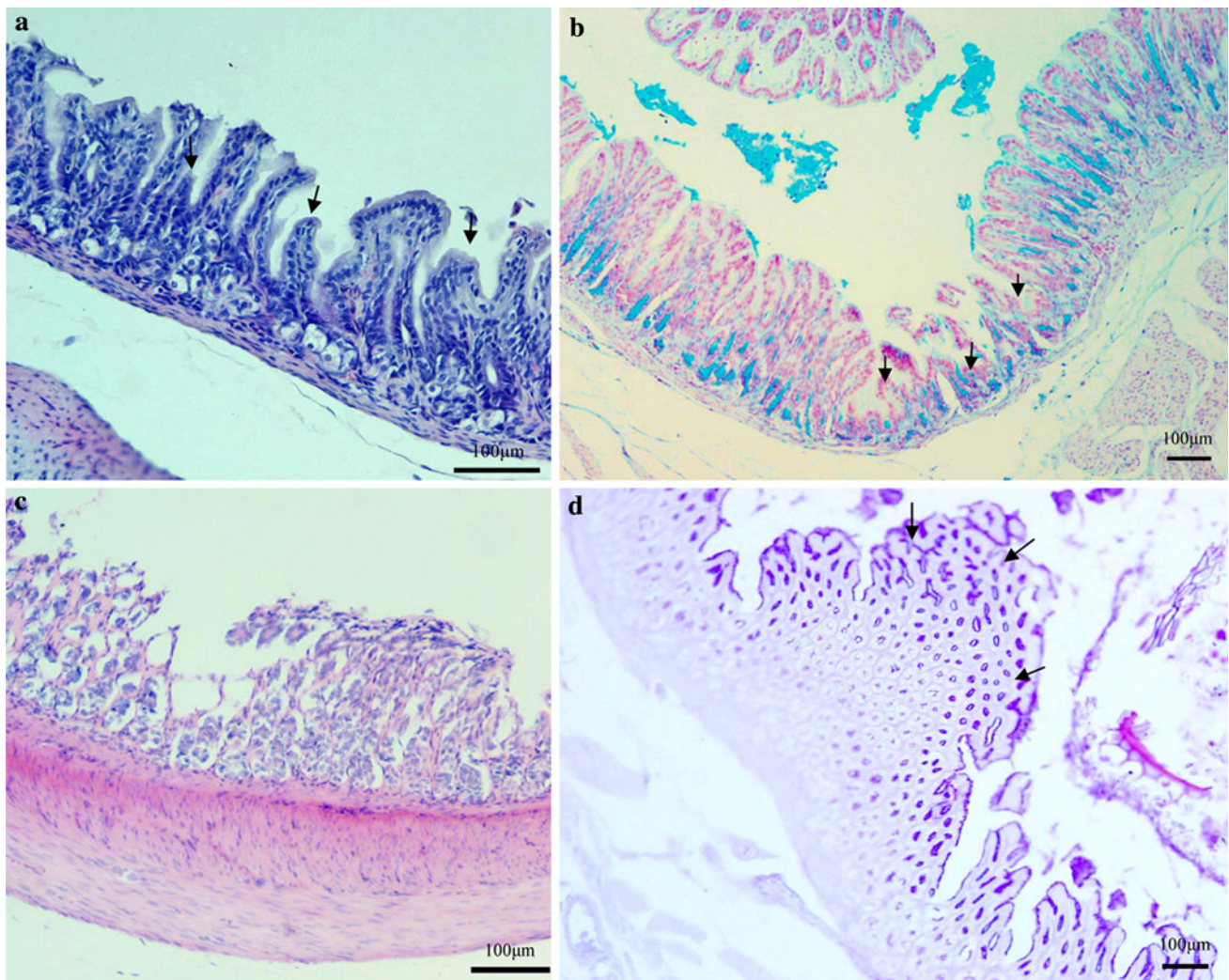


Fig. 3 Histopathological findings in the gastric mucosa of Mongolian gerbils. **a, b** Intestinal metaplasia forming villus-like structures (arrows) in the mucosa of the pyloric antrum. **c** Erosion events in the antrum mucosa. Not only the gastric epithelium but also the gastric glands were severely damaged. **d** Polyps consisting of several glands

in the mucosa. A large polyp like a cauliflower is found (arrows). Stains: H&E staining (a, c), pH 2.5 Alcian blue staining (b), PAS staining (d). Groups: ST 100 ppb administration group (b), ST 1,000 ppb administration group (a, c, d)

development of intestinal metaplasia. In other words, the administration of over 1,000 ppb of ST induced G1 arrest at the G1 check point of the cell cycle, but the administration of less than 100 ppb of ST produced a failure of G1 arrest [20]. Various histopathological changes were confirmed in most of the ST administered animals. These histopathological changes suggested a precancerous condition [16]. In our results, we were able to capture images of these precancerous lesions.

Histopathological examinations reconfirmed that *H. pylori* clearly produced metaplastic changes in the gastric mucosa of Mongolian gerbils, leading to atrophy and cancer of the stomach [21]. Ma et al. [22] reported that ST enhanced the development of *H. pylori*-induced gastric mucosal injury. Honda et al. [23] reported that *H. pylori*

infection was closely associated with the development of intestinal metaplasia; however, Shousha et al. [24] suggested the effect of factors other than *H. pylori* infection on the gastric mucosa. The present study indicated that other factors, such as ST, produced changes similar to those induced by *H. pylori* in the gastric mucosa of aged Mongolian gerbils.

PCNA is an auxiliary protein of DNA polymerase delta and is synthesized in the cell nucleus in the late G1 and S phases of the cell cycle [25]. It is a very reliable indicator of cell proliferative activity in tumorous and non-tumorous tissues [26]. We evaluated PCNA expression in several experimental groups. The PCNA LI rate was significantly greater in both of the ST-administered groups compared to that in the non-treated control group. These results indicate

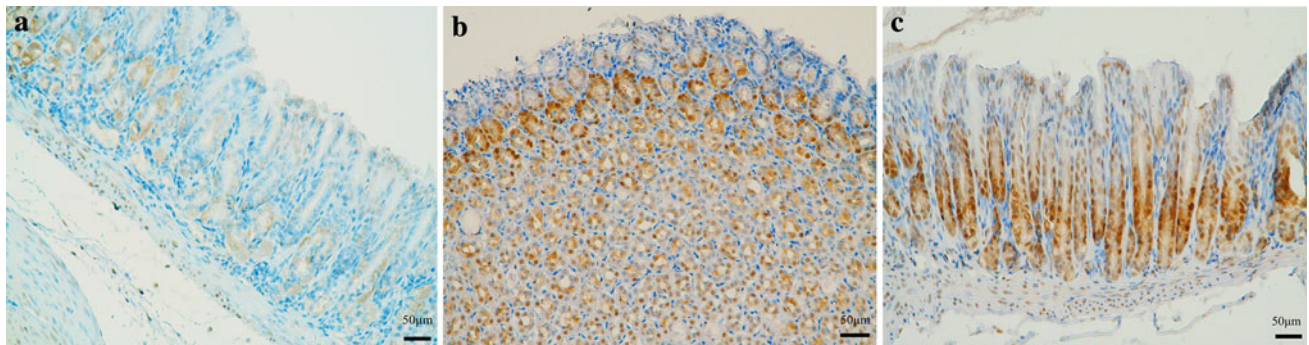


Fig. 4 Proliferating cell nuclear antigen (PCNA)-immunostaining images of the gastric mucosa of Mongolian gerbils. **a** Non-treated control animals, whose nuclei show almost negative reaction for PCNA antibody. **b, c** The gastric mucosa of ST-administered

Mongolian gerbils clearly has PCNA-positive nuclei. Stain: PCNA immunohistochemistry (**a–c**). Groups: non-treated control group (**a**), ST 1,000 ppb administration group (**b**), and ST 100 ppb administration group (**c**)

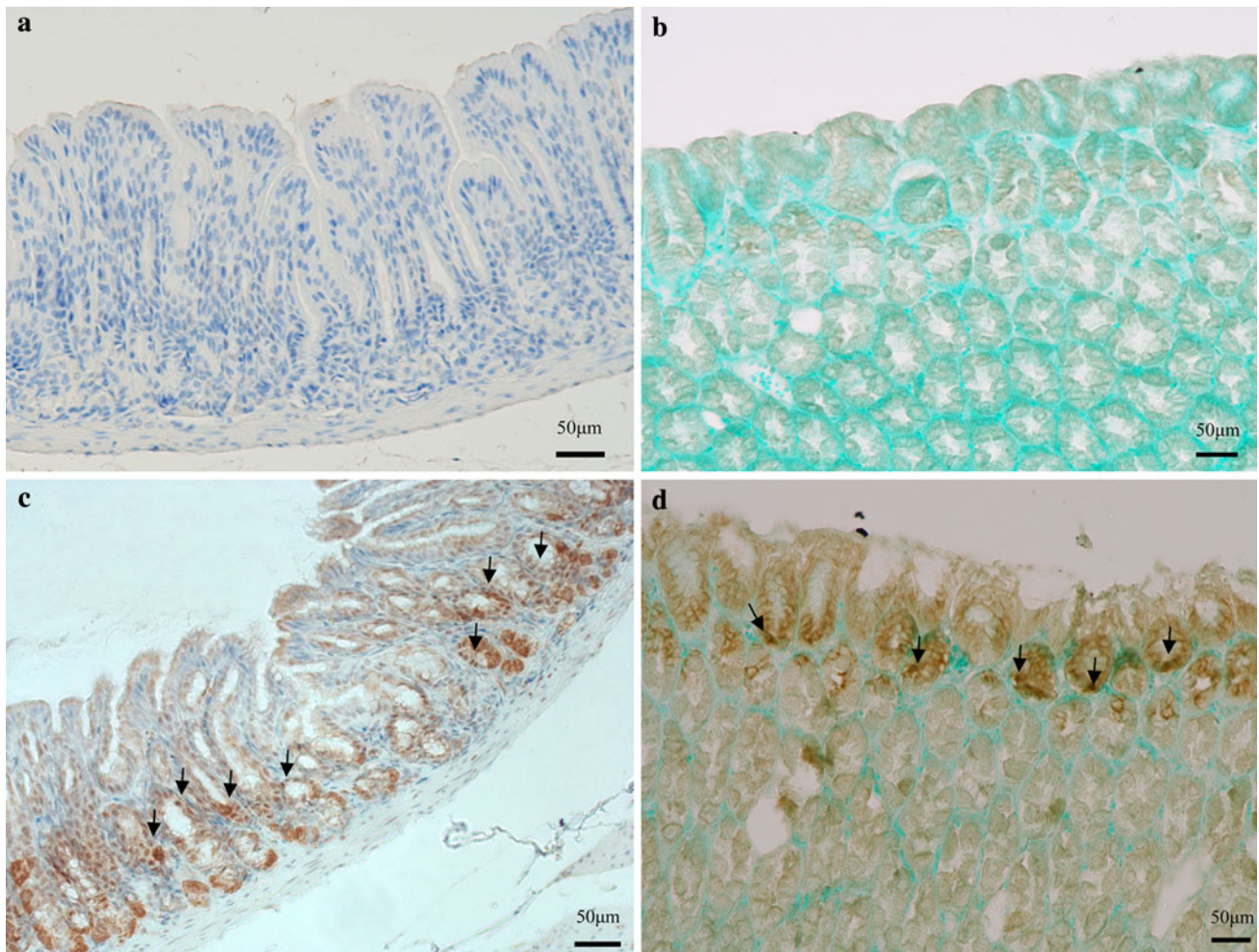


Fig. 5 p53 and MDM2 immunostaining images in the gastric mucosa of Mongolian gerbils. **a, b** Non-treated control gerbils, whose nuclei are negative on p53 and MDM2 immunostaining. **c, d** p53 and MDM2 expressions are observed in the gastric mucosa from ST-administered

gerbils. Faintly stained cells are seen in the mucous glands. The *arrows* indicate positive nuclei. Stains: p53 immunohistochemistry (**a, c**), MDM2 immunohistochemistry (**b, d**). Groups: non-treated control group (**a, b**), ST 1,000 ppb administration group (**c, d**)

Table 2 Proliferating cell nuclear antigen (PCNA) labeling index (LI), p53 positive index (PI), and MDM2 LI in the ST-administered groups

Group	<i>n</i>	PCNA LI (%) ^a	P53 PI (%) ^b	MDM2 LI (%) ^b
Non-treated control	11	15.3 ± 6.7	0 ± 0.1	0 ± 0
ST (100 ppb) administration	7	29.6 ^c ± 12.7	4.0 ^d ± 4.4	2.1 ^d ± 2.7
ST (1,000 ppb) administration	13	29.7 ^c ± 13.9	5.5 ^d ± 4.7	1.7 ^d ± 1.5

^a The results represent the mean ± SD. The data were analyzed by one-way analysis of variance (ANOVA) followed by Tukey's multiple comparison test

^b The results represent the mean ± SD. The data were analyzed by Mann–Whitney's *U*-test adjusted by the Bonferroni method

^c *P* < 0.05 compared with the non-treated control group

^d *P* < 0.01 compared with the non-treated control group

that ST changes the patterns of active cell proliferation in the gastric glands.

The p53 gene is a tumor suppressor gene that is most frequently expressed at the time of transformation to a malignant tumor, including to those of gastric cancer [27]. In this study, p53 PI expression was significantly greater in the gastric mucosa of both ST-administered groups compared to that in the non-treated control group. The p53 expression was identified in occasional epithelial cells that were concentrated in the neck region, as reported by previous studies [28]. The p53 gene expression has been reported in precancerous lesions [29]. This suggests that ST increases DNA damage in epithelial cells.

The MDM2 oncoprotein is a cellular inhibitor of the p53 tumor suppressor in that it can bind the transactivation domain of p53 and downregulate its ability to activate transcription. In certain cancers, MDM2 amplification is a common event and contributes to the inactivation of p53 [30, 31]. The interaction and relative ratios of p53 and MDM2 protein seem to play an important role in regulating cell division [32]. In this study, MDM2 LI expression was significantly greater in the gastric mucosa in both the ST 100 and 1,000 ppb-administered groups compared to that in the non-treated control group. Furthermore, Xie et al. [20] reported that, in an in vitro study to elucidate the mechanism of ST-induced carcinogenesis in mouse embryonic fibroblasts, the ST-induced activation and overexpression of MDM2 led to the suppression or inhibition of p53 gene function, and impairment of the DNA repair function resulted in the failure of G1 arrest; thus, ST induced the loss of genomic integrity, thereby, increasing carcinogenicity. In addition to the regulation of p53, MDM2 can also abrogate Rb-induced growth arrest and interact with the S-phase-promoting transcription factor E2F1/DP1 and activate it [20, 33–35]. In response to DNA damage, the p53 regulated pathway involves several of its downstream genes, including p21, cyclin-dependent kinases, Rb, and E2F. The effects of alteration of any of these downstream components may be similar to those of p53 inactivation, and, consequently, lead to failure of function

of the entire pathway [36]. This indicates that ST promotes the malignant transformation of cells.

We administered ST to aged Mongolian gerbils to examine its carcinogenicity. The mean lifespan of Mongolian gerbils is reportedly about 3 years [37]. If a crude extrapolation is made, 7 weeks corresponds to a human age of 3–4 years, 26 weeks to 14 years old, and 1 year to 25 years old [38]. Therefore, the Mongolian gerbils at the start of this study were estimated to be in their fifties in terms of human age.

The mortality rates of gastric cancer for men and women increase greatly with age [11]. Furthermore, aging factors are closely involved in the extension of atrophic gastritis [39]. Our results indicated that the environmental toxic substance ST produced the changes seen in the gastric mucosa of aged Mongolian gerbils and suggested that ST induced gastric carcinogenesis in the gastric mucosa. The mechanism of these ST-induced histopathological changes remains unclear, so further detailed studies on the base arrangement of genes with regard to their carcinogenic effect are needed.

Acknowledgments We are grateful to Y. Makino, K. Kawahara, T. Kishida, N. Eshima, Y. Yamaoka, R. Hamanaka, and S. Ishii from Oita University Faculty of Medicine, Japan, and N. Ebine of Doshisha University, Faculty of Health and Sports Science, Japan, for their helpful guidance in the preparation of this manuscript. We also thank A. Okamoto, M. Hikida, M. Yoshikawa, M. Tamori, Y. Miyanari, Y. Takakura, S. Sonoda, Y. Sakamoto, T. Shinohara, H. Akashi, and all staff members of the Department of Matrix Medicine, Oita University Faculty of Medicine, Japan, for their technical assistance in this study. This work was supported by Grants-in-Aid for Scientific Research from the Ministry of Education, Culture, Sports, Science and Technology of Japan (17390176).

References

1. Marshall BJ, Armstrong JA, Mcgechie DB, Glancy RJ. Attempt to fulfil Koch's postulates for pyloric *Campylobacter*. *Med J Aust*. 1985;142:436–9.
2. Sakaki N, Momma K, Yamada Y, Tadokoro Y, Tajima T. *Helicobacter pylori* infection and the development of atrophic

- gastritis assessed by endoscopy. *Eur J Gastroenterol Hepatol.* 1992;4(Suppl 1):S85–7.
3. Parsonnet J, Vandersteen D, Goates J, Sibley RK, Pritikin J, Chang Y. *Helicobacter pylori* infection in intestinal- and diffuse-type gastric adenocarcinomas. *J Natl Cancer Inst.* 1991;83:640–3.
 4. Asaka M, Kimura T, Kudo M, Takeda H, Mitani S, Miyazaki T, et al. Relationship of *Helicobacter pylori* to serum pepsinogens in an asymptomatic Japanese population. *Gastroenterology.* 1992;102:760–6.
 5. Kato H, Sobue T, Katanoda K, Saito Y, Tsukuma H, Saruki N, et al. Cancer statistics in Japan '2008'. Tokyo: Center for Cancer Control and Information Services, National Cancer Center Japan; 2008. p. 62–9.
 6. Matsuda T, Marugame T, Kamo K, Katanoda K, Ajiki W, Sobue T; Japan Cancer Surveillance Research Group. Cancer incidence and incidence rates in Japan in 2003: based on data from 13 population-based cancer registries in the Monitoring of Cancer Incidence in Japan (MCIJ) Project. *Jpn J Clin Oncol.* 2009;39:850–8.
 7. Zhang C, Yamada N, Wu YL, Wen M, Matsuhisa T, Matsukura N. *Helicobacter pylori* infection, glandular atrophy and intestinal metaplasia in superficial gastritis, gastric erosion, erosive gastritis, gastric ulcer and early gastric cancer. *World J Gastroenterol.* 2005;11:791–6.
 8. Atalla MM, Hassanein NM, El-Beih AA, Youssef YA. Mycotoxin production in wheat grains by different *Aspergilli* in relation to different relative humidities and storage periods. *Nahrung/Food.* 2003;47:6–10.
 9. Chu FS. Mycotoxins: food contamination, mechanism, carcinogenic potential and preventive measures. *Mutat Res.* 1991;259:291–306.
 10. Xie TX, Wang FR, Wang JL, Zhang ZD. Sterigmatocystin induced adenocarcinoma of the lung and atypical hyperplasia of glandular stomach in mice. *Chin J Cancer Res.* 1991;3:31–4.
 11. Truong Minh P, Fujino Y, Yoshimura T, Tokui N, Mizoue T, Yatsuya H, et al. Mortality and incidence rates of stomach cancer in the JACC Study. *J Epidemiol.* 2005;15(Suppl 2):S89–97.
 12. Khan N, Shariff N, Cobbold M, Bruton R, Ainsworth JA, Sinclair AJ, et al. Cytomegalovirus seropositivity drives the CD8 T cell repertoire toward greater clonality in healthy elderly individuals. *J Immunol.* 2002;169:1984–92.
 13. Shimamoto C, Hirata I, Hiraike Y, Takeuchi N, Nomura T, Katsu K. Evaluation of gastric motor activity in the elderly by electrogastrography and the ¹³C-acetate breath test. *Gerontology.* 2002;48:381–6.
 14. Kusunoki M, Misumi J, Aoki K, Shimada T, Matsuo N, Sumiyoshi H, et al. Long-term administration of sterigmatocystin with drinking water in *Helicobacter pylori*-infected aged Mongolian gerbils enhances carcinogenesis in the gastric mucosa. *J Phys Fit Nutr Immunol.* 2009;19:8–16.
 15. Terao K. Sterigmatocystin—a masked potent carcinogenic mycotoxin. *J Toxicol.* 1983;2:77–110.
 16. Watanabe T, Tada M, Nagai H, Sasaki S, Nakao M. *Helicobacter pylori* infection induces gastric cancer in Mongolian gerbils. *Gastroenterology.* 1998;115:642–8.
 17. Ma F, Misumi J, Zhao W, Aoki K, Kudo M. Long-term treatment with sterigmatocystin, a fungus toxin, enhances the development of intestinal metaplasia of gastric mucosa in *Helicobacter pylori*-infected Mongolian gerbils. *Scand J Gastroenterol.* 2003;4:360–9.
 18. Jones NL, Shannon PT, Cutz E, Yeager H, Sherman PM. Increase in proliferation and apoptosis of gastric epithelial cells early in the natural history of *Helicobacter pylori* infection. *Am J Pathol.* 1997;151:1695–703.
 19. Korkolopoulou P, Christodoulou P, Kapralos P, Exarchakos M, Bisbiroula A, Hadjiyannakis M, et al. The role of p53, MDM2 and c-erb B-2 oncoproteins, epidermal growth factor receptor and proliferation markers in the prognosis of urinary bladder cancer. *Pathol Res Pract.* 1997;193:767–75.
 20. Xie TX, Misumi J, Aoki K, Zhao WY, Liu SY. Absence of p53-mediated G1 arrest with induction of MDM2 in sterigmatocystin-treated cells. *Int J Oncol.* 2000;17:737–42.
 21. Correa P. Chronic gastritis: a clinico-pathological classification. *Am J Gastroenterol.* 1988;83:504–9.
 22. Ma F, Zhao W, Kudo M, Aoki K, Misumi J. Inhibition of vacuolation toxin activity of *Helicobacter pylori* by iodine, nitrite and potentiation by sodium chloride, sterigmatocystin and fluoride. *Toxicol In Vitro.* 2002;16:531–7.
 23. Honda S, Fujioka T, Tokieda M, Satoh R, Nishizono A, Nasu M. Development of *Helicobacter pylori*-induced gastric carcinoma in Mongolian gerbils. *Cancer Res.* 1998;58:4255–9.
 24. Shousha S, El-Sherif AM, El-Guneid A, Arnaout AH, Murraylyon IM. *Helicobacter pylori* and intestinal metaplasia: comparison between British and Yemeni patients. *Am J Gastroenterol.* 1993;88:1373–6.
 25. Shimizu T, Usuda N, Yamada T, Sugeno A, Iida F. Proliferative activity of human thyroid tumors evaluated by proliferating cell nuclear antigen/cyclin immunohistochemical studies. *Cancer.* 1993;71:2807–12.
 26. Filipe MI, Mendes R, Lane DP, Morris RW. Assessment of proliferating cell nuclear antigen expression in precursor stages of gastric carcinoma using the PC10 antibody to PCNA. *Histopathology.* 1993;22:349–54.
 27. Fritsche M, Haessler C, Brandner G. Induction of nuclear accumulation of the tumor-suppressor protein p53 by DNA-damaging agents. *Oncogene.* 1993;8:307–18.
 28. Hsu PI, Lai KH, Chien EJ, Lin CK, Lo GH, Jou HS, et al. Impact of bacterial eradication on the cell proliferation and p53 protein accumulation in *Helicobacter pylori*-associated gastritis. *Anticancer Res.* 2000;20:1221–8.
 29. Ochiai A, Yamauchi Y, Hirohashi S. p53 mutations in the non-neoplastic mucosa of the human stomach showing intestinal metaplasia. *Int J Cancer.* 1996;69:28–33.
 30. Kussie PH, Gorina S, Marechal V, Elenbaas B, Moreau J, Levine AJ, et al. Structure of the MDM2 oncoprotein bound to the p53 tumor suppressor transactivation domain. *Science.* 1996;274:948–53.
 31. Fuchs SY, Adler V, Buschmann T, Wu X, Ronai Z. Mdm2 association with p53 targets its ubiquitination. *Oncogene.* 1998;17:2543–7.
 32. Momand J, Zambetti GP, Olson DC, George D, Levine AJ. The mdm-2 oncogene product forms a complex with the p53 protein and inhibits p53-mediated transactivation. *Cell.* 1992;69:1237–45.
 33. Xiao ZX, Chen J, Levine AJ, Modjtahedi N, Xing J, Sellers WR, et al. Interaction between the retinoblastoma protein and the oncoprotein MDM2. *Nature.* 1995;375:694–8.
 34. Dubs-Poterszman MC, Tocque B, Wasylyk B. MDM2 transformation in the absence of p53 and abrogation of the p107 G1 cell-cycle arrest. *Oncogene.* 1995;11:2445–9.
 35. Martin K, Trouche D, Hagemeyer C, Sørensen TS, La Thangue NB, Kouzarides T. Stimulation of E2F1/DP1 transcriptional activity by MDM2 oncoprotein. *Nature.* 1995;375:691–4.
 36. Agarwal ML, Taylor WR, Chernov MV, Chernova OB, Stark GR. The p53 network. *J Biol Chem.* 1998;273:1–4.
 37. Schmiedt RA, Mills JH, Adams JC. Tuning and suppression in auditory nerve fibers of aged gerbils raised in quiet or noise. *Hear Res.* 1990;45:221–6.
 38. Ikeno T, Ota H, Sugiyama A, Ishida K, Katsuyama T, Genta RM, et al. *Helicobacter pylori*-induced chronic active gastritis, intestinal metaplasia, and gastric ulcer in Mongolian gerbils. *Am J Pathol.* 1999;154:951–60.
 39. Kimura K. Chronological transition of the fundic-pyloric border determined by stepwise biopsy of the lesser and greater curvatures of the stomach. *Gastroenterology.* 1972;63:584–92.